Cholecystitis

Lawrence M. Knab, MD[a], Anne-Marie Boller, MD[b],
David M. Mahvi, MD[b,*]

KEYWORDS

• Acute cholecystitis • Chronic cholecystitis • Acalculous cholecystitis • Gallstones • Cholecystectomy

KEY POINTS

- Disorders of the gallbladder are the most common surgical diseases treated by the general surgeon.
- Risk factors for gallstones include advanced age, female gender, obesity, and certain ethnicities, including North American Indian.
- The gold standard treatment of acute cholecystitis is a laparoscopic cholecystectomy.
- Operating early in the disease course decreases overall hospital days and does not lead to increased complications, conversion to open procedures, or mortality.
- Cholecystitis during pregnancy is a challenging problem for surgeons. Operative intervention is generally safe for both mother and fetus, given the improved morbidity of the laparoscopic approach compared with open, although increased caution should be exercised in women with gallstone pancreatitis.

OVERVIEW

Gallstone disease is an ancient problem. Autopsies on Egyptian mummies have shown gallstones from at least 3500 years ago.[1] Disorders of the gallbladder are the most common surgical diseases treated by a general surgeon. More than 700,000 cholecystectomies are performed in the United States every year, costing about 6.5 billion dollars. This situation makes gallbladder disease the most costly digestive disorder.[2] This article focuses specifically on the pathophysiology, diagnosis, and treatment of acute cholecystitis (calculous and acalculous), as well as chronic cholecystitis.

EPIDEMIOLOGY

It is estimated that 20 to 25 million Americans (10%–15% of the population) have gallstones.[2] Most people with gallstones are asymptomatic.[3] Population-based studies

[a] Department of Surgery, Northwestern University Feinberg School of Medicine, Lurie Building Room 3-250, 303 East Superior Street, Chicago, IL 60611, USA; [b] Department of Surgery, Northwestern University Feinberg School of Medicine, NMH/Arkes Family Pavilion Suite 650, 676 North Saint Clair, Chicago, IL 60611, USA
* Corresponding author. Department of Surgery, Northwestern University Feinberg School of Medicine, NMH/Arkes Family Pavilion Suite 650, 676 North Saint Clair, Chicago, IL 60611.
E-mail address: dmahvi@nmh.org

Surg Clin N Am 94 (2014) 455–470
http://dx.doi.org/10.1016/j.suc.2014.01.005 surgical.theclinics.com
0039-6109/14/$ – see front matter

suggest that 10% to 18% of those with silent gallstones develop biliary pain and 7% require operative intervention.[4,5] One percent to 4% of those with gallstones develop complications such as acute cholecystitis, gallstone pancreatitis, and choledocholithiasis.[6]

The prevalence of cholelithiasis in North America varies widely depending on ethnicity. North American Indians have a prevalence as high as 73% in women older than 30 years. White Americans have a lower prevalence of gallstones, at 16.6% in women and 7.9% in men. Asian populations have intermediate rates of 5% to 20%, black African Americans have rates of about 14%, and black Africans have low rates, at less than 5%.[2]

Incidence of gallbladder disease increases with age, making this an important issue in our aging population. A study of gallstone prevalence at necropsy in the United Kingdom reported an incidence of gallstones of 24% in women 50 to 59 years old, increasing to 30% in the ninth decade. The rates for men are 18% in the 50-year-old to 59-year-old range, with an increase to 29% in the ninth decade.[7]

RISK FACTORS

The development of cholelithiasis is multifactorial. Advancing age is a risk factor for gallstone development in all ethnic groups. Gallstones are rarely reported in infants and children, but prevalence markedly increases in individuals older than 20 years, particularly in women. Female gender is also a risk factor. Women are at a greater risk of having gallstones as well as undergoing operative intervention. Estrogen seems to play a critical role in this increased risk, because pregnancy, parity, and estrogen replacement therapy all increase the risk of gallstones.[2] Obesity is another risk factor for gallstone development, likely caused by increased hepatic secretion of cholesterol. This risk factor is stronger in women than men. Obese women have a 7-fold increase of developing gallstones compared with their normal weight female counterparts. Ironically, rapid weight loss is also a risk factor for gallstone development and occurs as in as many as 25% to 30% of patients after bariatric surgery.[2]

GALLSTONE FORMATION

The type of gallstone and location in the biliary system vary depending on ethnicity. Most of the gallstones encountered in developed countries are cholesterol stones (about 80%) with a few being pigmented (black stones).

The pathogenesis of cholesterol gallstones is dependent on multiple factors: cholesterol supersaturation in the bile, crystal nucleation, gallbladder dysmotility, and gallbladder absorption.

Pigmented gallstones can be divided into black stones and brown stones. Black stones consist of calcium bilirubinate and mucin glycoproteins.[2] Black stones are generally associated with hemolytic conditions or cirrhosis, which cause increased levels of unconjugated bilirubin.[8] These stones are usually located in the gallbladder. Brown stones are typically associated with bacterial infection, are more prevalent in Asian populations, and are usually located elsewhere in the biliary tree as opposed to the gallbladder.[8]

ACUTE CHOLECYSTITIS

Acute cholecystitis accounts for 14% to 30% of cholecystectomies.[9–11]

Pathophysiology

Acute cholecystitis is defined as inflammation of the gallbladder, generally caused by obstruction of the cystic duct. The most common causes of cystic duct obstruction

are gallstones or biliary sludge, although other less common causes include a mass (primary tumor or gallbladder polyp), parasites, or foreign bodies (bullets have been described).[12] Cholecystitis can also occur in the absence of gallstones and is known as acalculous cholecystitis, which is reviewed in a later section.

When the cystic duct is obstructed, the gallbladder mucosa continues to produce mucus but has no outlet for drainage, leading to increased gallbladder pressure, venous stasis, followed by arterial stasis and gallbladder ischemia and necrosis (Fig. 1). Necrotic tissue can then lead to complications such as gallbladder perforation and empyema.

Clinical Presentation

Most patients who present with acute cholecystitis have symptoms of right upper quadrant or epigastric abdominal pain. Often, this pain starts as diffuse epigastric abdominal pain and develops a bandlike quality radiating around the back. As gallbladder inflammation worsens, the pain tends to localize in the right upper quadrant. Patients may also describe previous episodes of biliary colic, in which the pain comes in waves (hence the term colic) and is sometimes postprandial, particularly after high-fat meals. Patients often describe being awakened in the middle of the night by the pain. Nausea, vomiting, and anorexia are commonly associated with acute cholecystitis.

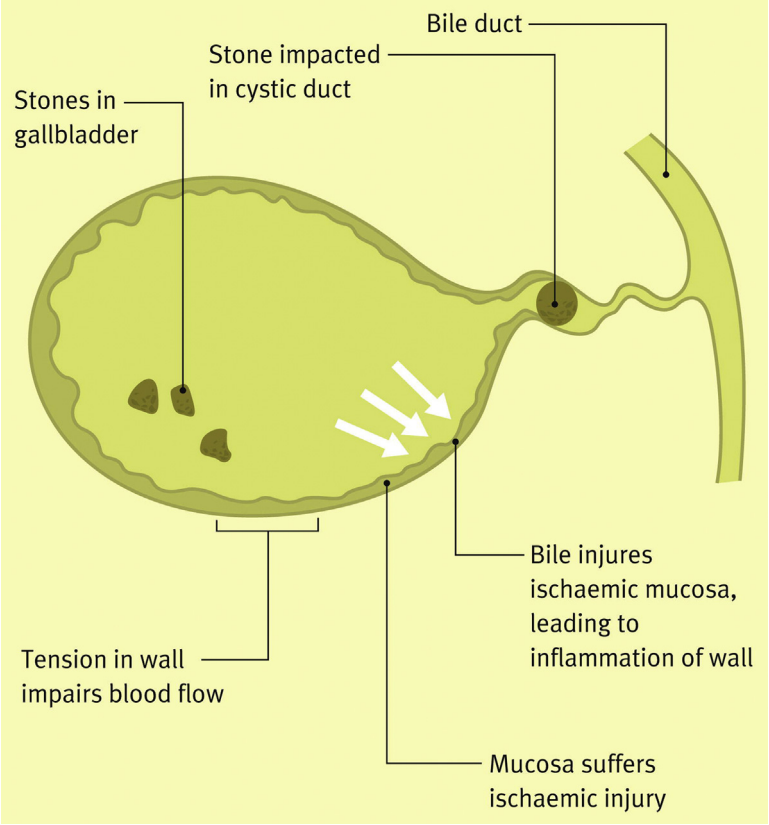

Fig. 1. Pathogenesis of acute cholecystitis secondary to impacted gallstone in the cystic duct. *Arrows* indicate interaction of the ischemic mucosa with bile resulting in inflammation. (*From* Sethi H, Johnson CD. Gallstones. Medicine 2011;39(10):625; with permission.)

Physical examination can show tachycardia and a fever. Patients generally have tenderness to palpation in the epigastric region or right upper quadrant. Some patients may have a Murphy's sign, which is cessation of inspiration with palpation in the right upper quadrant over the gallbladder.

As with most inflammatory conditions, acute cholecystitis is usually associated with leukocytosis, although the presentation can be variable. Only 32% to 53% of patients have a fever on presentation, and 51% to 53% have leukocytosis.[13,14] Evaluation of a group of 103 patients with acute cholecystitis showed that most patients (71%) do not present with a fever within the first 8 hours of arrival to the hospital.[15] Sixty-eight percent of those patients did have a leukocytosis (white blood cells >12,000), and 25% had both a fever and leukocytosis.[15] Of the patients with gangrenous cholecystitis, 41% presented with fever and 73% with leukocytosis.[15] The diagnosis must always be made based on a combination of history, physical findings, laboratory values, and diagnostic imaging if needed.

When a patient presents with symptoms consistent with acute cholecystitis, the possibility of choledocholithiasis must also be entertained, because this can alter operative plans. Relevant clinical findings such as clay-colored stools or dark urine can provide clues. Increased bilirubin and liver enzyme levels and dilated common bile duct on imaging can also indicate choledocholithiasis.

Imaging

Multiple imaging modalities can be used to diagnose acute cholecystitis including transabdominal ultrasonography (US), cholescintigraphy, and magnetic resonance imaging (MRI); however, US and cholescintigraphy are used most frequently. Transabdominal US is the ideal imaging modality to detect gallstones and measure the bile duct diameter. Findings consistent with acute cholecystitis include a thickened gallbladder wall (>4 mm) secondary to edema, gallstones or sludge, and pericholecystic fluid (**Fig. 2**). US has the advantages of being noninvasive, quick, relatively inexpensive, and widely available, even after hours. One major limitation of US is poor visualization when intraluminal gas is present between the probe and the gallbladder.

Cholescintigraphy is an alternative method of imaging and uses technetium-labeled hepatic 2,6-dimethyl-iminodiacetic acid (HIDA). HIDA is injected intravenously, taken up by the liver, and excreted in the bile and is therefore able to visualize the biliary system. A normal scan shows uptake in the liver, gallbladder, bile duct, and duodenum within an hour of injection (**Fig. 3**A). If the cystic duct is obstructed, as typically found in acute cholecystitis, the gallbladder is not visualized on this scan (see **Fig. 3**B). The main advantage of HIDA is its superior sensitivity in diagnosing acute cholecystitis. However, there are several disadvantages. Compared with US, cholescintigraphy is more expensive, time intensive (it takes several hours compared with 10–15 minutes for US), requires skilled staff, and is often not available after hours. It also exposes patients to ionizing radiation and provides information limited to the hepatobiliary system, whereas US and MRI do not expose patients to radiation and can provide added information outside the hepatobiliary system.

MRI is increasingly used for hepatobiliary imaging as the technology and diagnostic accuracy improve (**Fig. 4**). Advantages of MRI are that it can provide information about the whole abdomen in addition to the biliary system, and it does not expose the patient to ionizing radiation. Disadvantages of MRI, similar to HIDA, are limited availability after hours and length of time needed for the examination.

Multiple studies have evaluated the sensitivity and specificity of these diagnostic studies in acute cholecystitis.[16–19] A meta-analysis evaluating US, HIDA, and MRI, showed a range of sensitivities in US from 50% to 100%, with a summary estimate

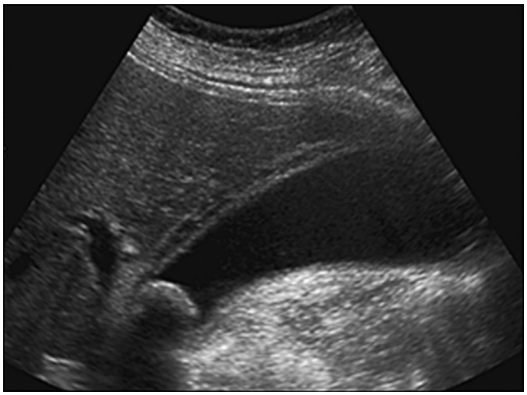

Fig. 2. Acute cholecystitis. Sagittal sonogram showing a single calculus impacted in the neck of the gallbladder. Additional findings include a mildly distended gallbladder and striated wall thickening. (*From* Glanc P, Maxwell C. Acute abdomen in pregnancy: role of sonography. J Ultrasound Med 2010;29(10):1458; with permission.)

of 81%, HIDA with sensitivities from 78% to 100% and a summary estimate of 96%, and MRI with a range of 50% to 91% and a summary estimate of 85%.[16] A head-to-head comparison was evaluated in 11 studies (1199 patients) in the meta-analysis, and again HIDA was found to be significantly superior to US. The sensitivity of HIDA was 94% compared with 80% for US.[16] In most studies, HIDA is significantly more sensitive compared with US and MRI for diagnosing acute cholecystitis.

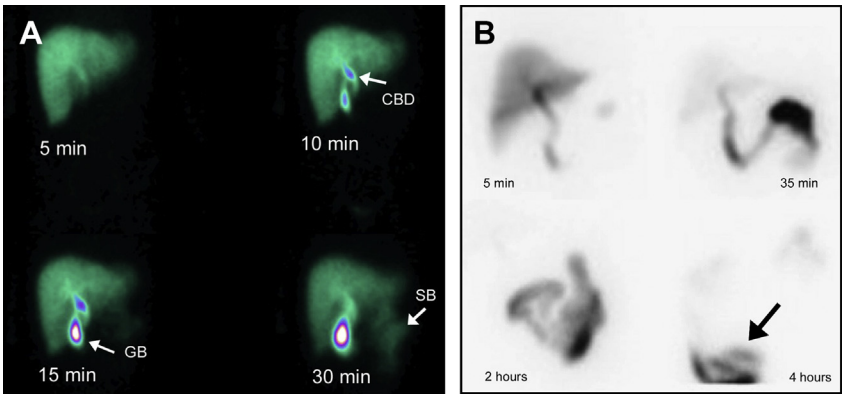

Fig. 3. (*A*) Normal technetium 99m HIDA series. Selected anterior planar images from an HIDA examination show prompt and uniform tracer uptake by the hepatic parenchyma, followed by excretion of activity into the intrahepatic and extrahepatic biliary tree and normal filling of the gallbladder. Activity then proceeds unimpeded into the proximal small bowel. This entire sequence is usually complete within 30 to 60 minutes. CBD, common bile duct; GB, gallbladder; SB, small bowel. (*B*) Acute cholecystitis. Anterior planar images from an HIDA examination show uniform tracer uptake within the hepatic parenchyma followed by rapid clearance of hepatic activity with visualization of the biliary tree and unimpeded flow into the distal small bowel (*arrow*). However, there is nonvisualization of the gallbladder even on delayed imaging up to 4 hours, consistent with acute cholecystitis. (*From* Lambie H, Cook AM, Scarsbrook AF, et al. Tc99m-hepatobiliary iminodiacetic acid (HIDA) scintigraphy in clinical practice. Clin Radiol 2011;66(11):1095–6; with permission.)

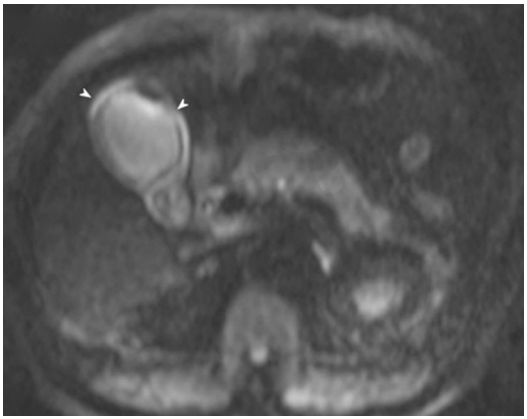

Fig. 4. Diffusion-weighted MRI of abdomen showing acute cholecystitis and pancreatitis; arrowheads indicate gallbladder wall thickening. (*From* Lee NK, Kim S, Kim GH, et al. Diffusion-weighted imaging of biliopancreatic disorders: correlation with conventional magnetic resonance imaging. World J Gastroenterol 2012;18(31):4106; with permission.)

The advantages and disadvantages must be evaluated for each individual patient when deciding which type of imaging to use. If acute cholecystitis is highly suspected, US is likely the ideal choice given its widespread availability, quick administration time, low cost, and patient safety profile. If the diagnosis of acute cholecystitis is in question and 1 imaging study was equivocal, HIDA is likely the better choice, given its superior sensitivity compared with both US and MRI. The role of MRI is emerging as the availability and accuracy both improve.

Management of Acute Cholecystitis

Early surgical management of acute cholecystitis was confined to stone extraction. Cholecystostomy was initially described by Bobbs and Sims and perfected by Kocher and Tait.[20] The first cholecystectomy was performed in 1882 by Carl Langenbuch in Berlin, and for the following 100 years, open cholecystectomy was the gold standard for cholecystitis.[20–22] This gold standard changed after the first laparoscopic cholecystectomy was performed by a French surgeon in 1987. Over the course of a few years, laparoscopic cholecystectomy became more common than open cholecystectomy, and within a decade, laparoscopic cholecystectomy replaced the open equivalent as the gold standard of therapy for acute cholecystitis.[21] Data from Maryland indicate that before the advent of laparoscopy in 1985 the rate of laparoscopic cholecystectomy was 0 patients per 1000 people compared with open cholecystectomy with a rate of 1.65 per 1000 people. Just 7 years later, in 1992, the rate of laparoscopic surgery increased to 1.66 per 1000 people, and the open cholecystectomy rate decreased dramatically to 0.51 per 1000 people.[9] There is little debate that the gold standard treatment of acute cholecystitis is a cholecystectomy, and this has been the case for many years. The laparoscopic approach, as well as the timing of the cholecystectomy, has evolved rapidly over the last 20 years.

Timing of Operation

Two main treatment pathways have been used when dealing with acute cholecystitis. The early cholecystectomy (EC) school of thought endorses performing a cholecystectomy during the initial hospital stay. The idea is to reduce overall hospital stay and prevent subsequent readmissions secondary to cholecystitis or symptomatic

cholelithiasis. The delayed cholecystectomy (DC) group endorses treating the patient with antibiotics during the initial hospitalization and performing the cholecystectomy about 4 to 8 weeks after the initial insult. The advantages posited for this approach include operating in a field with less inflammation and therefore less potential for complications and conversion to an open procedure.

Several meta-analyses and randomized control trials have evaluated this question, and most of the data indicate that an EC is safe and results in a shorter overall hospital stay (**Table 1**). The hypothesis that a DC significantly reduces complications and conversion rates has not been validated by existing studies.

One randomized control trial by Lo divided 45 patients into the EC group and 41 patients in the DC group. The EC group underwent a laparoscopic cholecystectomy within 72 hours of admission, and the DC group was managed nonoperatively during the initial hospitalization and readmitted 8 to 12 weeks later for an elective procedure. Twenty percent of the DC group underwent an interval procedure because of failure to respond to initial nonoperative treatment. The EC group had a longer median operative time compared with the DC group (135 minutes vs 105 minutes, respectively) although there was no significant difference in conversion to an open procedure (11% in the EC vs 23% in the DC group).[27] There was no significant difference in morbidity between the 2 groups, although there was a trend toward an increase in complications in the DC group (13% in the EC vs 29% in the DC; $P = .07$). The EC group had a significantly shorter overall hospital stay compared with the DC group (5 days vs 7 days, respectively).[23]

A second randomized control trial by Johansson included 74 patients in the EC group (who underwent operation within 7 days from onset of symptoms) and 71 patients in the DC group (elective operation 6–8 weeks later). In this study, 25% of the DC group underwent an interval procedure because of failure to respond to nonoperative management. There was no significant difference in the operating time or the conversion rates between the 2 groups.[24]

A meta-analysis[28] evaluated 5 randomized control trials with a total of 223 in the EC group and 228 in the DC group. The EC underwent an operation within 1 week of symptom onset, and the DC group underwent an elective operation within 6 to 12 weeks. There was a trend toward increased postoperative bile leak in the EC group compared with the DC group, although no significant difference in postoperative

Table 1
Early versus late cholecystectomy

		n		Early vs Late Cholecystectomy				
Reference	Study Type	EC	LC	Operating Room Time (min)	Conversion to Open (%)	Complications (%)	Mortality (%)	Hospital Stay (d)
Lo et al,[23] 1998	RCT	45	41	135 vs 105 ($P = .02$)	11 vs 23 (NS)	13 vs 29 ($P = .07$)	0 vs 0	6 vs 11 ($P<.001$)
Johansson et al,[24] 2003	RCT	74	71	98 vs 100	31 vs 29	No significant difference	0 vs 0	5 vs 8 ($P = .05$)
Lai et al,[25] 1998	RCT	53	51	123 vs 107 ($P = .04$)	-	9 vs 8 (NS)	0 vs 0	7.6 vs 11.6 ($P<.001$)
Kolla et al,[26] 2004	RCT	20	20	104 vs 93 (NS)	25 vs 25 (NS)	20 vs 15 (NS)	0 vs 0	4.1 vs 10.1 ($P = .02$)

Abbreviations: LC, late cholecystectomy; n, number; NS, not significant; RCT, randomized controlled trial.

complications or conversion rate was reported. The overall hospital stay was significantly shorter in the EC group compared with the DC group by 4 days ($P<.001$).

When evaluating these studies, a few trends become apparent. One is that EC in acute cholecystitis is safe and is not associated with a statistically significant increase in complications or conversion rate. Patients who undergo EC also have an overall shorter hospital stay compared with the DC group. In the DC group, there are many patients (about 20%) who require emergency surgery for persistent symptoms and are therefore at increased risk for conversion to an open procedure.

TYPE OF OPERATION

Laparoscopic Cholecystectomy

As mentioned earlier, laparoscopic cholecystectomy is the gold standard treatment of acute cholecystitis. The shift from open to laparoscopic cholecystectomy occurred in the late 1980s. As surgeon training progressed in laparoscopy, many surgeons started using a single-incision approach known as single-incision laparoscopic cholecystectomy (SILC). The advantages of SILC include the advantages of conventional multiport laparoscopic cholecystectomy (CMLC) over the open approach, as well as theoretic improved cosmetic result and decreased postoperative pain secondary to a decreased incision length; however, neither of these parameters has been consistently validated in the literature. The main disadvantages of SILC are increased operative time, which can lead to increased intraoperative blood loss and hospital stay, as well as increased overall costs compared with conventional laparoscopic surgery.

Many studies evaluating SILC exclude patients with acute cholecystitis. The inflammatory condition inherent in acute cholecystitis tends to make an already challenging laparoscopic dissection and critical view of safety even more difficult when facing the added technical considerations of a single port. One study evaluating risk factors for prolonged operating time in SILC using multivariate analysis found that acute cholecystitis and body mass index were independent risk factors.[29] In addition, prolonged operating time was associated with statistically significant intraoperative blood loss and hospital length of stay.[29] A review evaluating 30 studies showed that acute cholecystitis was a significant risk factor for SILC failure, with a success rate of 60% in SILC studies including patients with acute cholecystitis versus 93% success in those studies excluding acute cholecystitis.[30]

A prospective randomized trial with 79 patients (about 25% with acute cholecystitis) who underwent either SILC or CMLC reported a statistically significant increase in overall cost associated with the SILC group compared with the CMLC ($2100 more, on average). Several quality-of-life measures were evaluated, including postoperative pain (followed out to 6 months), body image impact, and satisfaction with cosmetic results, and no statistically significant differences were found.[31]

A meta-analysis[32] that evaluated 12 randomized prospective trials (only 2 included patients with acute cholecystitis) comparing SILC with CMLC reported that mean operating time was significantly increased in the SILC group compared with the CMLC group (63 vs 46 minutes, respectively), and the conversion rate to laparotomy was similar. The pain scores 6 hours and 24 hours postoperatively were not statistically significant between the 2 groups, and although the length of hospital stay for the SILC group trended toward being less than the CMLC group (2.0 days vs 2.2 days), the difference was not significant. There were no significant differences in postoperative morbidity, bleeding, incisional hernias, or surgical site infections. Only 3 studies investigated patient satisfaction with cosmetic outcome, and based on survey results, the SILC patients reported statistically significant improved cosmetic results.

Using SILC in patients with acute cholecystitis should be approached with caution. Although technically possible, SILC often results in increased operative time, blood loss, and overall expense, without a clear advantage in postoperative pain or decreased hospital stay.

Open Cholecystectomy

Laparoscopic cholecystectomy has replaced open cholecystectomy as the gold standard treatment of acute cholecystitis, and many reported studies have repeatedly proved the safety of the procedure after initial skepticism about bile duct injury rates. These studies have reported bile duct injury rates ranging between about 0.3% and 0.4% after accounting for the initial learning curve after the introduction of the laparoscopic cholecystectomy.[33–35] Studies have also shown similar morbidity and mortality between laparoscopic and open surgery and decreased length of hospital stay and postoperative pain.[21,36] We argue that 100% of operations for acute cholecystitis should be initiated laparoscopically. The surgeon must be aware of the variable biliary anatomy (**Fig. 5**) and ensure a critical view of safety. The critical view of safety is a view of the gallbladder after dissection showing only 2 structures entering the gallbladder: the cystic artery and cystic duct (**Fig. 6**). If it is determined that the operation cannot be completed safely and the critical view of safety not obtained via a laparoscopic dissection, conversion to an open operation is always an option. In some of the most experienced hands, conversion to an open procedure occurs in about 1% to 2% of patients undergoing an elective procedure, although the rate increases in acute cholecystitis.[37,38] There is little downside to an attempt at laparoscopy in a patient without previous upper abdominal surgery. A less frequent indication to convert to an open procedure is concern for gallbladder malignancy.

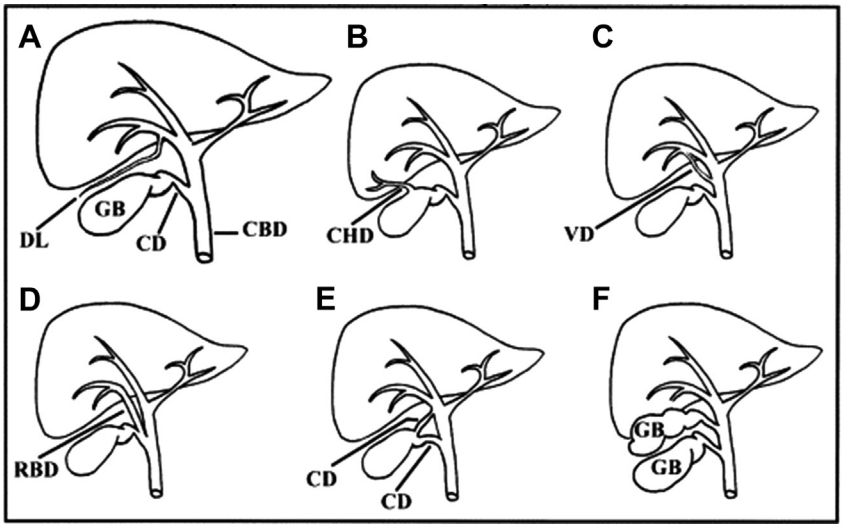

Fig. 5. Schematic view of main variations of the biliary system anatomy in the triangle of Calot and the gallbladder fossa. (*A*) Duct of Luschka (DL), (*B*) cystohepatic duct (CHD), (*C*) vaginali ductuli (VD), (*D*) variant drainage of right posterior sector, (*E*) duplication of cystic duct (CD), (*F*) duplication of gallbladder (GB). CBD, common bile duct; RBD, right bile duct. (*From* Sharif K, de Ville de Goyet J. Bile duct of Luschka leading to bile leak after cholecystectomy–revisiting the biliary anatomy. J Pediatr Surg 2003;38(11):E22; with permission.)

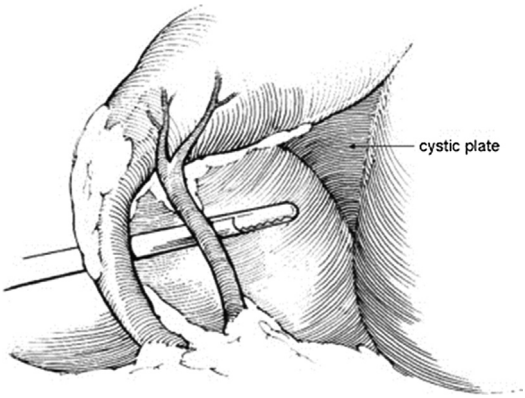

Fig. 6. Critical view of safety, showing only the cystic duct and artery entering directly into the gallbladder with the bottom of the liver bed visible. (*From* Strasberg SM, Hertl M, Soper NJ. An analysis of the problem of biliary injury during laparoscopic cholecystectomy. J Am Coll Surg 1995;180(1):113; with permission.)

Intraoperative Imaging of the Common Bile Duct

Intraoperative imaging of the common bile duct is a widely debated topic among surgeons. Surgeons perform intraoperative cholangiograms routinely, selectively, or not at all. There are 2 main reasons to perform intraoperative imaging of the biliary anatomy: to delineate the relevant anatomy when there is question during the dissection and to evaluate the presence of common bile duct stones. Many surgeons agree that those patients who present with clinical evidence, laboratory values, or imaging consistent with choledocholithiasis, including gallstone pancreatitis, jaundice, increased liver enzyme levels, or a dilated common bile duct, should undergo common bile duct evaluation by some method. There are varying strategies to evaluate the common bile duct perioperatively, including preoperative or postoperative endoscopic retrograde cholangiopancreatography, magnetic resonance cholangiopancreatography, or intraoperative imaging modalities, including cholangiography or US. The most efficient and cost-effective method varies according to the resources available at any given institution and must be individualized.

For those patients with no preoperative evidence of common bile duct stones, the decision to evaluate the common bile duct is controversial. In a series of patients undergoing laparoscopic cholecystectomy with routine intraoperative cholangiography and no preoperative evidence of common bile duct stones, 4% had common bile duct stones.[39,40] The false-positive rate was between 0.8% and 1.6%.[39] In a series of patients undergoing laparoscopic cholecystectomy with selective intraoperative cholangiography and no preoperative evidence of choledocholithiasis, only about 0.6% became symptomatic from retained common bile duct stones.[39] These data suggest that only about 15% of silent retained common duct stones cause symptoms. The decision to proceed with intraoperative biliary imaging should be based on a patient's risk factors and presentation.

ACALCULOUS CHOLECYSTITIS

Pathophysiology

Acalculous cholecystitis (ACC) differs from calculous acute cholecystitis because it is not precipitated by occlusion of the cystic duct by gallstones or biliary sludge. Two

percent to 15% of patients with acute cholecystitis do not have stone disease.[41] ACC is generally the result of biliary stasis and gallbladder ischemia, although the pathophysiology has yet to be determined and is likely multifactorial. It is often associated with critical illness, such as septic shock, severe trauma, burns, and major nonbiliary operations.[41] Biliary stasis can also be a precipitating cause as a result of prolonged fasting or hyperalimentation. ACC has been associated with mortality as high as 41%.[42]

ACC is associated with an increased frequency of gallbladder complications, such as gallbladder perforation, gangrenous gallbladder, and emphysematous gallbladder. Reports indicate that 40% to 100% of patients presenting with ACC have one of these complications.[41]

Clinical Presentation

ACC can be difficult to diagnose, because the clinical manifestations are varied and often nondescript. Patients can present in a similar fashion to acute calculous cholecystitis with right upper quadrant abdominal pain, nausea, vomiting, anorexia, and fever, although sometimes, the main complaint is vague abdominal pain. In the critically ill setting, a high index of suspicion must be maintained, because ACC is often a diagnosis of exclusion in a critically ill patient with persistent fevers and leukocytosis. ACC can result in rapid decompensation and mortality.

Imaging

Imaging modalities in ACC are similar to those of acute calculous cholecystitis, with US findings of gallbladder wall thickening, pericholecystic fluid, and a distended gallbladder, although no gallstones or biliary sludge are present. In critically ill patients with cardiac or renal insufficiency, gallbladder wall edema may be secondary to fluid overload, and interpretation of transabdominal US can be difficult. In these scenarios, an HIDA scan can be more efficacious.

TREATMENT

The preferred treatment of ACC is cholecystectomy, although many patients diagnosed with ACC are poor surgical candidates. Often, a temporizing percutaneous cholecystostomy is performed, with the plan for a subsequent cholecystectomy once the patient has improved clinically and is fit to undergo an operation.

There is, of course, debate as to which patients are operative candidates and when cholecystostomy should be used instead of cholecystectomy. The literature on this topic is varied and difficult to analyze, given the disparities between treatment groups and the mixing of patients with calculous cholecystitis and ACC. Some studies show increased perioperative morbidity and complications with cholecystectomy[43] and others with percutaneous cholecystostomy.[44] Most of these studies do not include enough patients to meaningfully determine survival rates. One study evaluated nationwide outcomes of percutaneous cholecystostomy for both calculous cholecystitis and ACC. More than 58,000 ACC cases were included, and multivariate analyses indicated that those who underwent a percutaneous cholecystostomy had decreased odds of complications, although they had increased risk of mortality, length of hospital stay, and overall expense.[45] This study suggests that older patients with increased comorbidities tend to undergo cholecystostomy and that more patients should be considered for cholecystectomy. If the patient is a surgical candidate, a cholecystectomy should be performed, because this generally leads to overall less hospital length of stay, decreased expense, and complication rates, and mortality has not been shown

to be increased. If a patient is not a surgical candidate, a percutaneous cholecystostomy is a useful option, but many patients are readmitted with biliary complications and require a cholecystectomy at a later time.

CHRONIC CHOLECYSTITIS

Chronic cholecystitis and biliary colic account for 79% of cholecystectomies.[10]

Pathophysiology

Chronic cholecystitis occurs when a patient develops repeated occurrences of gallbladder inflammation, leading to gradual scarring and gallbladder dysfunction.[46] The most common cause is gallstones intermittently obstructing the cystic duct, leading to biliary colic or episodic waves of epigastric pain and discomfort. The cystic duct is commonly obstructed for some time, leading to gallbladder distention and inflammation, followed by relief of the obstruction (the stone or sludge no longer obstructs the cystic duct) and cessation of pain. This cycle can be repeated for months or years, leading to a chronic gallbladder inflammation and scarring. Histologically, chronic cholecystitis can be characterized by an increase in subepithelial and subserosal fibrosis, as well as a mononuclear cell infiltrate secondary to this chronic inflammation.[46]

Clinical Presentation

Similar to acute cholecystitis, the most common presenting symptom of chronic cholecystitis is pain. As described earlier in the section on pathophysiology, chronic cholecystitis is often caused by repeated inflammatory episodes, and patients often report episodes of biliary colic, which can last for hours at a time followed by a pain-free period. These episodes are generally described as epigastric or right upper quadrant pain, which can radiate to the back. Nausea, vomiting, and anorexia can also be associated with these episodes. Chronic cholecystitis and acute cholecystitis are a spectrum of diseases, and an episode of biliary colic caused by cystic duct obstruction can precipitate acute cholecystitis if the obstruction is not relieved. Many patients who present with chronic cholecystitis do not have pain at the time of presentation but endorse the characteristic history. Physical examination is often unremarkable as well, unless the patient is experiencing pain.

Imaging

Transabdominal US is the main imaging modality used to diagnose chronic cholecystitis. Most patients with chronic cholecystitis have evidence of gallstones on US. These imaging findings combined with a history of abdominal pain consistent with biliary colic are generally diagnostic of biliary colic and chronic cholecystitis.

Management

The treatment of chronic cholecystitis is an elective cholecystectomy. Most patients with typical biliary symptoms and gallstones on imaging have improvement of symptoms after a cholecystectomy.

SPECIAL CONSIDERATIONS: ACUTE CHOLECYSTITIS IN PREGNANCY

Gallstone-related disease remains the second most common nongynecologic condition requiring surgery in pregnant patients (acute appendicitis is more prevalent).[47] Acute cholecystitis in pregnancy presents a challenging clinical scenario, which has been the cause of some debate regarding surgical management in this patient

population. The surgical dogma advocated by many surgeons in the past has been to pursue nonoperative management of pregnant patients until after delivery, when a cholecystectomy can be performed without risk to the fetus. This treatment algorithm has been challenged in recent years, because laparoscopic cholecystectomy has proved to be a safe operation, which is tolerated well in most patient populations.

Pregnant patients are at increased risk of developing gallstones, because of increased levels of estrogen and progesterone. Estrogen increases cholesterol secretion and progesterone decreases bile acid secretion as well as decreasing gallbladder contractility caused by smooth muscle inhibition.[48] Gallstones have been reported in as many as 1% to 3% of pregnant patients and biliary sludge in as many as 30%, although acute cholecystitis is not more common in pregnancy. About 0.1% of pregnant patients develop acute cholecystitis.[48]

There are no prospective randomized trials comparing nonoperative management and cholecystectomy in pregnant women with acute cholecystitis. A comprehensive literature search that evaluated a total of 277 laparoscopic cholecystectomies performed during pregnancy showed a fetal demise rate of 2.2%. Of the 6 reported cases of fetal demise, 4 of the cases involved gallstone pancreatitis.[49] The reported fetal death rates after nonoperative management are varied and range from 0% to 12%. One report indicated a 12% fetal death rate after nonoperative management of biliary colic and acute cholecystitis and an increase to 60% if gallstone pancreatitis developed.[50] An additional factor to consider aside from fetal death rates is the added morbidity of recurrent episodes of biliary colic and cholecystitis in those women treated nonoperatively. Individual reports indicate a wide variability in relapse rate. One study reported recurrence rates of 92%, 64%, and 44% in the first, second, and third trimesters, respectively.[51] Another study reported lower rates of 20%, 45%, and 35% in the first, second, and third trimesters, respectively.[47] In this series, the rates of premature contractions, labor induction for treatment, and preterm delivery were all higher in the nonoperative group compared with the cholecystectomy group.

SUMMARY

It is estimated that up to 15% of the American population have gallstones, and disorders of the gallbladder are the most common diseases confronting general surgeons. It is important for general surgeons to be aware that EC for acute cholecystitis has been shown to decrease overall hospital days without leading to increased complications, mortality, or conversion to open procedures. Although cholecystitis is one of the most common general surgical diseases, variations in cause, clinical presentation, and severity require that surgeons fully understand the disease process and treatment approaches.

REFERENCES

1. Stinton LM, Myers RP, Shaffer EA. Epidemiology of gallstones. Gastroenterol Clin North Am 2010;39(2):157–69, vii.
2. Shaffer EA. Gallstone disease: epidemiology of gallbladder stone disease. Best Pract Res Clin Gastroenterol 2006;20(6):981–96.
3. Halldestam I, Enell EL, Kullman E, et al. Development of symptoms and complications in individuals with asymptomatic gallstones. Br J Surg 2004;91(6):734–8.
4. McSherry CK, Ferstenberg H, Calhoun WF, et al. The natural history of diagnosed gallstone disease in symptomatic and asymptomatic patients. Ann Surg 1985;202(1):59–63.

5. Ransohoff DF, Gracie WA, Wolfenson LB, et al. Prophylactic cholecystectomy or expectant management for silent gallstones. A decision analysis to assess survival. Ann Intern Med 1983;99(2):199–204.
6. Riall TS, Zhang D, Townsend CM Jr, et al. Failure to perform cholecystectomy for acute cholecystitis in elderly patients is associated with increased morbidity, mortality, and cost. J Am Coll Surg 2010;210(5):668–77, 677–9.
7. Bates T, Harrison M, Lowe D, et al. Longitudinal study of gall stone prevalence at necropsy. Gut 1992;33(1):103–7.
8. Venneman NG, van Erpecum KJ. Pathogenesis of gallstones. Gastroenterol Clin North Am 2010;39(2):171–83, vii.
9. Steiner CA, Bass EB, Talamini MA, et al. Surgical rates and operative mortality for open and laparoscopic cholecystectomy in Maryland. N Engl J Med 1994; 330(6):403–8.
10. Orlando R 3rd, Russell JC, Lynch J, et al. Laparoscopic cholecystectomy. A statewide experience. The Connecticut Laparoscopic Cholecystectomy Registry. Arch Surg 1993;128(5):494–8 [discussion: 498–9].
11. Pulvirenti E, Toro A, Gagner M, et al. Increased rate of cholecystectomies performed with doubtful or no indications after laparoscopy introduction: a single center experience. BMC Surg 2013;13:17.
12. Petersen JM, Knight TT. Gunshot cholecystitis. J Clin Gastroenterol 1995;21(4): 320–2.
13. Raine PA, Gunn AA. Acute cholecystitis. Br J Surg 1975;62(9):697–700.
14. Hafif A, Gutman M, Kaplan O, et al. The management of acute cholecystitis in elderly patients. Am Surg 1991;57(10):648–52.
15. Gruber PJ, Silverman RA, Gottesfeld S, et al. Presence of fever and leukocytosis in acute cholecystitis. Ann Emerg Med 1996;28(3):273–7.
16. Kiewiet JJ, Leeuwenburgh MM, Bipat S, et al. A systematic review and meta-analysis of diagnostic performance of imaging in acute cholecystitis. Radiology 2012;264(3):708–20.
17. Kalimi R, Gecelter GR, Caplin D, et al. Diagnosis of acute cholecystitis: sensitivity of sonography, cholescintigraphy, and combined sonography-cholescintigraphy. J Am Coll Surg 2001;193(6):609–13.
18. Chatziioannou SN, Moore WH, Ford PV, et al. Hepatobiliary scintigraphy is superior to abdominal ultrasonography in suspected acute cholecystitis. Surgery 2000;127(6):609–13.
19. Gill PT, Dillon E, Leahy AL, et al. Ultrasonography, HIDA scintigraphy or both in the diagnosis of acute cholecystitis? Br J Surg 1985;72(4):267–8.
20. Hardy KJ. Carl Langenbuch and the Lazarus Hospital: events and circumstances surrounding the first cholecystectomy. Aust N Z J Surg 1993;63(1): 56–64.
21. Soper NJ, Stockmann PT, Dunnegan DL, et al. Laparoscopic cholecystectomy. The new 'gold standard'? Arch Surg 1992;127(8):917–21 [discussion: 921–3].
22. Beal JM. Historical perspective of gallstone disease. Surg Gynecol Obstet 1984; 158(2):181–9.
23. Lo CM, Liu CL, Fan ST, et al. Prospective randomized study of early versus delayed laparoscopic cholecystectomy for acute cholecystitis. Ann Surg 1998; 227(4):461–7.
24. Johansson M, Thune A, Blomqvist A, et al. Management of acute cholecystitis in the laparoscopic era: results of a prospective, randomized clinical trial. J Gastrointest Surg 2003;7(5):642–5.

25. Lai PB, Kwong KH, Leung KL, et al. Randomized trial of early versus delayed laparoscopic cholecystectomy for acute cholecystitis. Br J Surg 1998;85(6): 764–7.
26. Kolla SB, Aggarwal S, Kumar A, et al. Early versus delayed laparoscopic cholecystectomy for acute cholecystitis: a prospective randomized trial. Surg Endosc 2004;18(9):1323–7.
27. Skouras C, Jarral O, Deshpande R, et al. Is early laparoscopic cholecystectomy for acute cholecystitis preferable to delayed surgery?: Best evidence topic (BET). Int J Surg 2012;10(5):250–8.
28. Gurusamy K, Samraj K, Gluud C, et al. Meta-analysis of randomized controlled trials on the safety and effectiveness of early versus delayed laparoscopic cholecystectomy for acute cholecystitis. Br J Surg 2010;97(2):141–50.
29. Sato N, Yabuki K, Shibao K, et al. Risk factors for a prolonged operative time in a single-incision laparoscopic cholecystectomy. HPB (Oxford) 2014;16(2):177–82.
30. Antoniou SA, Pointner R, Granderath FA. Single-incision laparoscopic cholecystectomy: a systematic review. Surg Endosc 2011;25(2):367–77.
31. Leung D, Yetasook AK, Carbray J, et al. Single-incision surgery has higher cost with equivalent pain and quality-of-life scores compared with multiple-incision laparoscopic cholecystectomy: a prospective randomized blinded comparison. J Am Coll Surg 2012;215(5):702–8.
32. Pisanu A, Reccia I, Porceddu G, et al. Meta-analysis of prospective randomized studies comparing single-incision laparoscopic cholecystectomy (SILC) and conventional multiport laparoscopic cholecystectomy (CMLC). J Gastrointest Surg 2012;16(9):1790–801.
33. Z'Graggen K, Wehrli H, Metzger A, et al. Complications of laparoscopic cholecystectomy in Switzerland. A prospective 3-year study of 10,174 patients. Swiss Association of Laparoscopic and Thoracoscopic Surgery. Surg Endosc 1998; 12(11):1303–10.
34. Nuzzo G, Giuliante F, Giovannini I, et al. Bile duct injury during laparoscopic cholecystectomy: results of an Italian national survey on 56 591 cholecystectomies. Arch Surg 2005;140(10):986–92.
35. Fletcher DR, Hobbs MS, Tan P, et al. Complications of cholecystectomy: risks of the laparoscopic approach and protective effects of operative cholangiography: a population-based study. Ann Surg 1999;229(4):449–57.
36. Lillemoe KD, Lin JW, Talamini MA, et al. Laparoscopic cholecystectomy as a "true" outpatient procedure: initial experience in 130 consecutive patients. J Gastrointest Surg 1999;3(1):44–9.
37. Wu JS, Dunnegan DL, Luttmann DR, et al. The evolution and maturation of laparoscopic cholecystectomy in an academic practice. J Am Coll Surg 1998; 186(5):554–60 [discussion: 560–1].
38. Lau H, Brooks DC. Transitions in laparoscopic cholecystectomy: the impact of ambulatory surgery. Surg Endosc 2002;16(2):323–6.
39. Metcalfe MS, Ong T, Bruening MH, et al. Is laparoscopic intraoperative cholangiogram a matter of routine? Am J Surg 2004;187(4):475–81.
40. Khan OA, Balaji S, Branagan G, et al. Randomized clinical trial of routine on-table cholangiography during laparoscopic cholecystectomy. Br J Surg 2011; 98(3):362–7.
41. Ryu JK, Ryu KH, Kim KH. Clinical features of acute acalculous cholecystitis. J Clin Gastroenterol 2003;36(2):166–9.
42. Kalliafas S, Ziegler DW, Flancbaum L, et al. Acute acalculous cholecystitis: incidence, risk factors, diagnosis, and outcome. Am Surg 1998;64(5):471–5.

43. Melloul E, Denys A, Demartines N, et al. Percutaneous drainage versus emergency cholecystectomy for the treatment of acute cholecystitis in critically ill patients: does it matter? World J Surg 2011;35(4):826–33.
44. Abi-Haidar Y, Sanchez V, Williams SA, et al. Revisiting percutaneous cholecystostomy for acute cholecystitis based on a 10-year experience. Arch Surg 2012; 147(5):416–22.
45. Anderson JE, Chang DC, Talamini MA. A nationwide examination of outcomes of percutaneous cholecystostomy compared with cholecystectomy for acute cholecystitis, 1998-2010. Surg Endosc 2013;27(9):3406–11.
46. Mulholland MW, Lillemoe K, Doherty GM, et al. Greenfield's surgery: scientific principles and practice. 4th edition. Philadelphia: Lippincott Williams & Wilkins; 2006. p. 2277.
47. Lu EJ, Curet MJ, El-Sayed YY, et al. Medical versus surgical management of biliary tract disease in pregnancy. Am J Surg 2004;188(6):755–9.
48. Gilo NB, Amini D, Landy HJ. Appendicitis and cholecystitis in pregnancy. Clin Obstet Gynecol 2009;52(4):586–96.
49. Jelin EB, Smink DS, Vernon AH, et al. Management of biliary tract disease during pregnancy: a decision analysis. Surg Endosc 2008;22(1):54–60.
50. Muench J, Albrink M, Serafini F, et al. Delay in treatment of biliary disease during pregnancy increases morbidity and can be avoided with safe laparoscopic cholecystectomy. Am Surg 2001;67(6):539–42 [discussion: 542–3].
51. Swisher SG, Schmit PJ, Hunt KK, et al. Biliary disease during pregnancy. Am J Surg 1994;168(6):576–9 [discussion: 580–1].